

## DT imaging promising for patients with brain injury

Dr. Nancy Rollins, chief of Radiology at Children's and professor of Radiology at UT Southwestern, is on the forefront of a new type of research called diffusion tensor imaging.

DTI provides information about how the brain is "wired" that is not provided by routine magnetic resonance imaging. An area of special interest is that of the limbic system, which is important in learning and memory. Many children with birth defects that affect the brain have learning and memory problems.

Other areas of the brain also are being studied with the help of DTI technology, and DTI has the potential to give insight into the short- and long-term effects of brain tumors on neuro-development and cognition in patients such as Valerie Ruiz.

Other applications of DTI include studying brain damage resulting from trauma and stroke. It is hoped that DTI will provide information as to why the pediatric brain is more "plastic" than the adult brain. That is, why a child's brain seems to be less severely affected by trauma and strokes.

### Exploring the applications

"DTI is a new and promising technique for studying how the brain is connected, as DTI shows the white matter that connects the brain and can distinguish one white matter tract from another," Dr. Rollins said. "Routine MRI has lim-

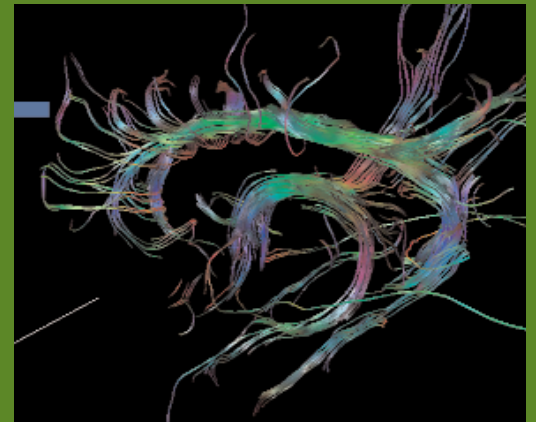
ited capacity to show separate white matter tracts. We are just beginning to explore the applications of this new technique in children with birth defects, brain tumors and brain injury from trauma, strokes, etc."

In DTI, image contrast is due to the inherent directional movement (anisotropy) of water within the brain. DTI provides information about white matter organization and architecture that is not possible with conventional MRI. Diffusion tensor data are displayed as two-dimensional color maps in which brightness indicates diffusion anisotropy and color indicates tract orientation (see images).

Dr. Rollins and her team at Children's are one of a few groups in the country using DTI technology for research in pediatrics, and they are coming up with breakthroughs that are generating excitement in the neuro-radiology community.

For example, Valerie's DTI could be used to identify the location of nerve fiber tracts before her tumor surgery, with the goal of avoiding the normal nerve fibers while cutting out the tumor. Furthermore, scientists can use DTI to examine the long-term effects of cancer therapy on the development of the nervous system after chemotherapy and radiation therapy.

Dr. Rollins and her team have published several major papers in the past year based on DTI research.



**ABOVE:** Lateral view of the fornices and cingulum of a normal patient. The cingulum and fornices have relatively high fractional anisotropy at birth and are easy to track; these structures are abnormal in many cerebral malformations.

**BELOW:** Coronal image of the fornices in a normal 9-year-old. The blue in the middle shows the column, green at the convergence shows the body, purple on the edges show the crura and the fibers on the sides show fimbria.

